

Advances in the Surgical Management of GI Stromal Tumors

**GIST Summit
September 22, 2012**



Kelly K. Hunt, M.D.
Professor of Surgery

THE UNIVERSITY OF TEXAS

**MD Anderson
Cancer Center**

Making Cancer History®

Agenda

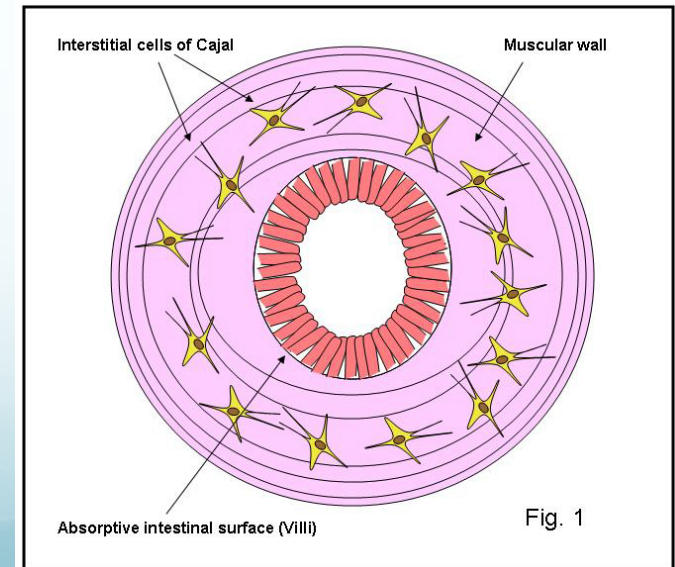
- Background information
- Overview of advances in diagnosis and treatment
- Surgical management of GISTs by anatomic site
- Future directions

Gastrointestinal Stromal Tumors

- GISTs are rare neoplasms requiring multidisciplinary management
- Management has been revolutionized with the introduction of tyrosine kinase inhibitors
- Rapid progress from bench to bedside
- Rigorous clinical investigation redefining the standards of care

Background

- Approximately 6000 new cases of GIST diagnosed in US each year
- Gastrointestinal stromal tumors (GISTs) are the most common mesenchymal tumor of the GI tract
- Thought to originate from the interstitial cells of Cajal
- Males and females affected equally
- Mean age of 63 yrs at diagnosis

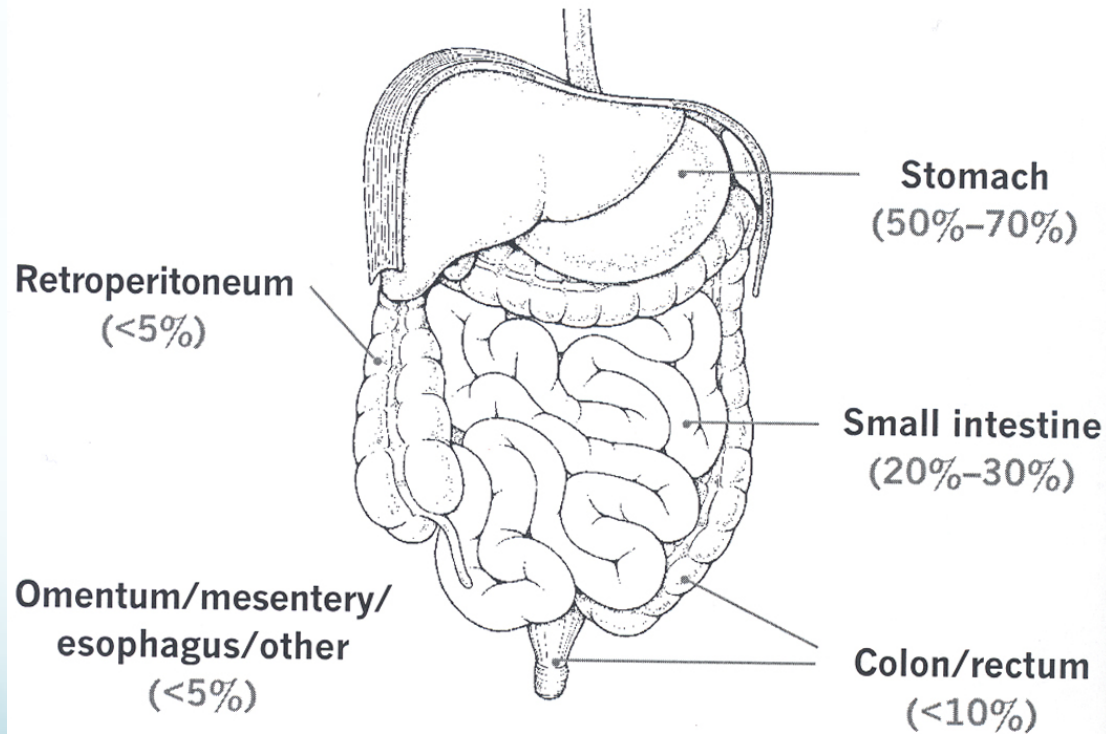


Diagnostic Criteria

- Anatomic Site: GI-tract, mesentery, omentum, retroperitoneum
- Appropriate histologic appearance
- CD117 (KIT receptor) immuno-reactivity

Distribution of GIST Throughout the GI Tract

Most common anatomic locations of GISTs.^{4,5,7,8}



Gastrointestinal Stromal Tumors

Clinical Presentation

Signs/symptoms related to location of tumor

- GI hemorrhage
- Abdominal mass
- Vague GI pain / discomfort
- Anorexia, weight loss, nausea, anemia
- Surgical emergencies – perforation, bleeding

Often asymptomatic, incidental finding

Establishing Diagnosis

- History and Physical Exam
- Laboratory Assessment
 - About 95% of GISTs are positive for KIT (CD117)
- Radiologic Assessment

CT chest/ abdomen/ pelvis

- è Mass
- è Absence regional lymph node metastases
- è Metastases: liver, implants

Prognostic Factors

Good prognosis

Tumor < 5 cm

Low mitotic rate
(< 2 /10 HPF)

Low proliferation index

Absence of necrosis

Gastric tumor

Age < 40 years

Poor prognosis

Tumor > 10 cm

High mitotic rate
(>5–10 /10 HPF)

Tumor Rupture

High proliferation index

Necrosis

Distal/extraintestinal tumor

Male gender

Surgical Principles

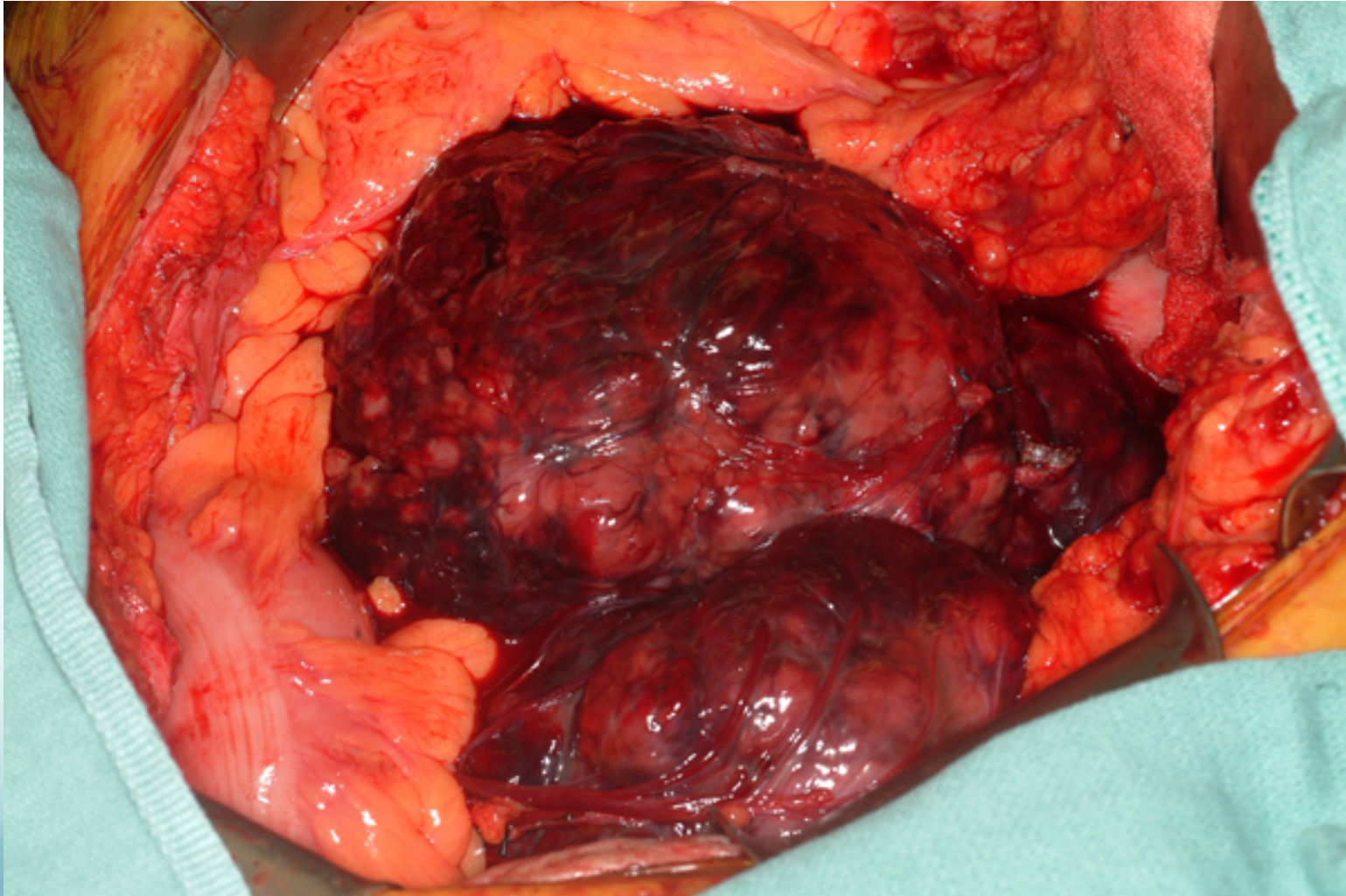
- Surgical resection is standard practice for localized GIST
 - Generally no role for radiation
 - GISTs are mostly refractory to standard chemotherapy
- Most recurrences distant rather than local
 - Liver or widespread intra-abdominal disease
 - Recurrence rates are about 50% at 5 years
- Goal of surgery: Achieve complete resection

- Aim is to resect the tumor with histologically negative margins
 - Small bowel 2-3 cm segmental resection
 - Stomach 1-2 cm wedge resection
- The pseudocapsule of the tumor should not be violated



Warning: Slides contain photographs of surgical specimens

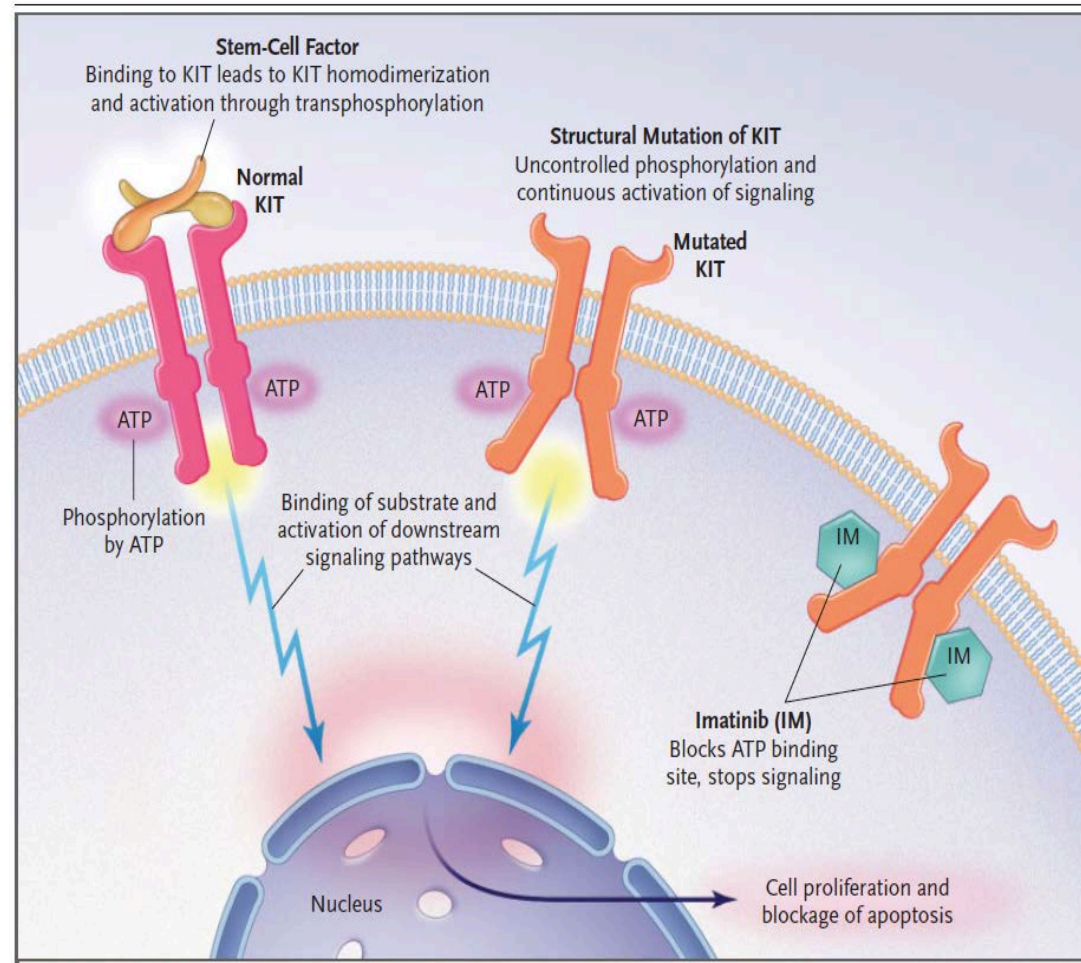
Small bowel GIST



Imatinib mesylate

- Effective in reducing recurrence after surgery and against metastases
- Considered for treating tumors before surgery (neoadjuvantly) when tumors are large or in anatomic sites that could benefit from reduction in tumor size before resection

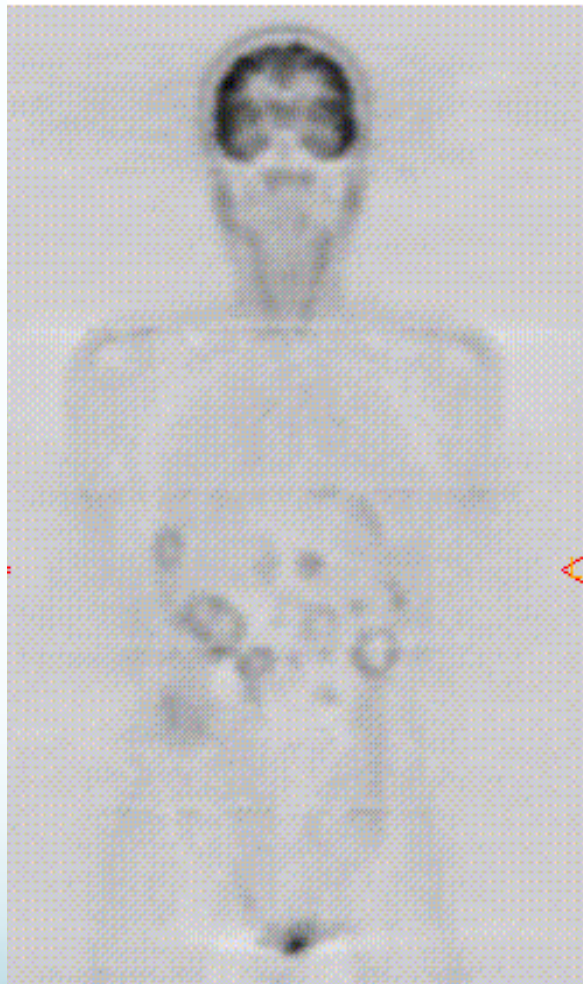Demetri G et al., N Engl J Med, 2004



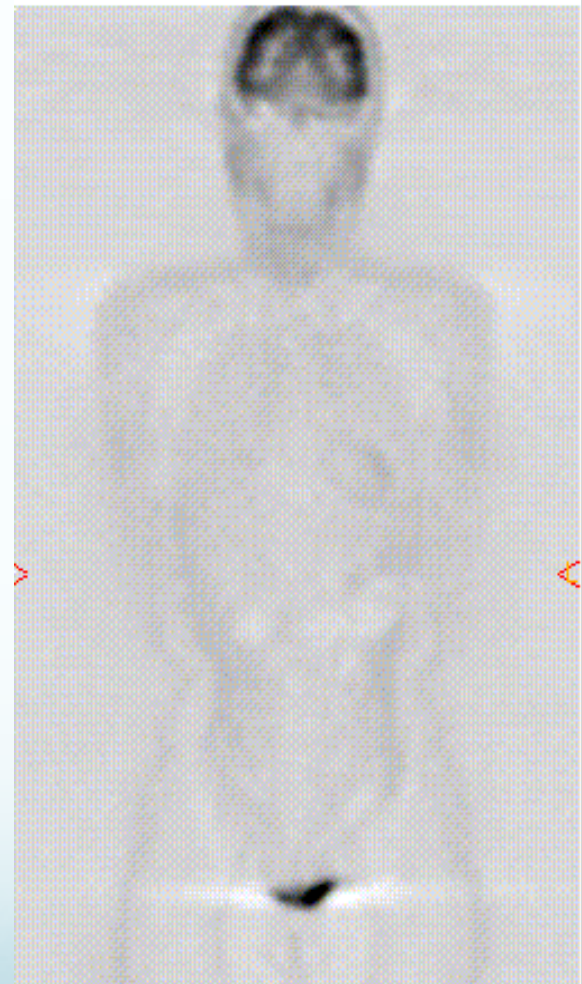
Neoadjuvant Imatinib

- Rationale:
 - Decrease the size of the tumor
 - Decrease the vascularity of the tumor
 - Diminish the extent of resection required
- For locally advanced primary GIST patients receiving neoadjuvant imatinib (Andtbacka R, et al. 2006):
 - 1% complete response, 73% partial response, 9% stable disease, 1% progressive disease
 - Responding patients had a median decrease in tumor volume of 85% (27-99%)

GIST Patient Treated With Imatinib: FDG-PET Scans Before/After



March 3, 2000

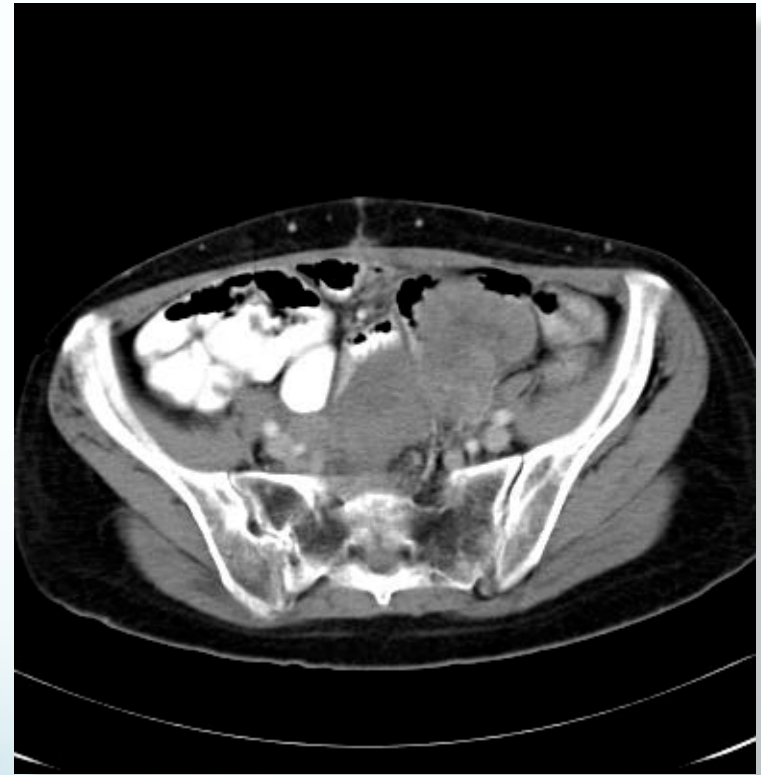
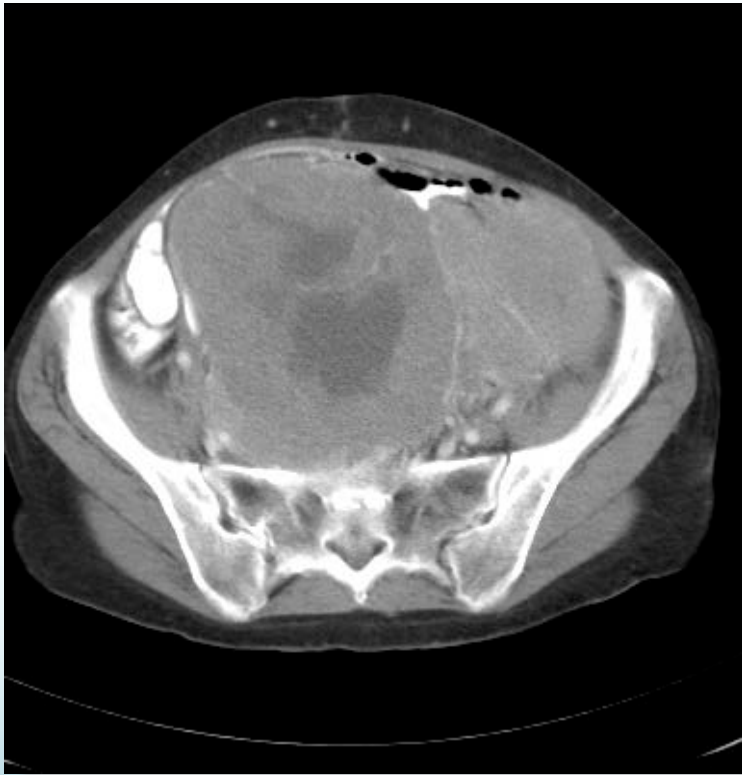
April 5, 2000

CT Scan Results: Decrease in Tumor Volume

June 27

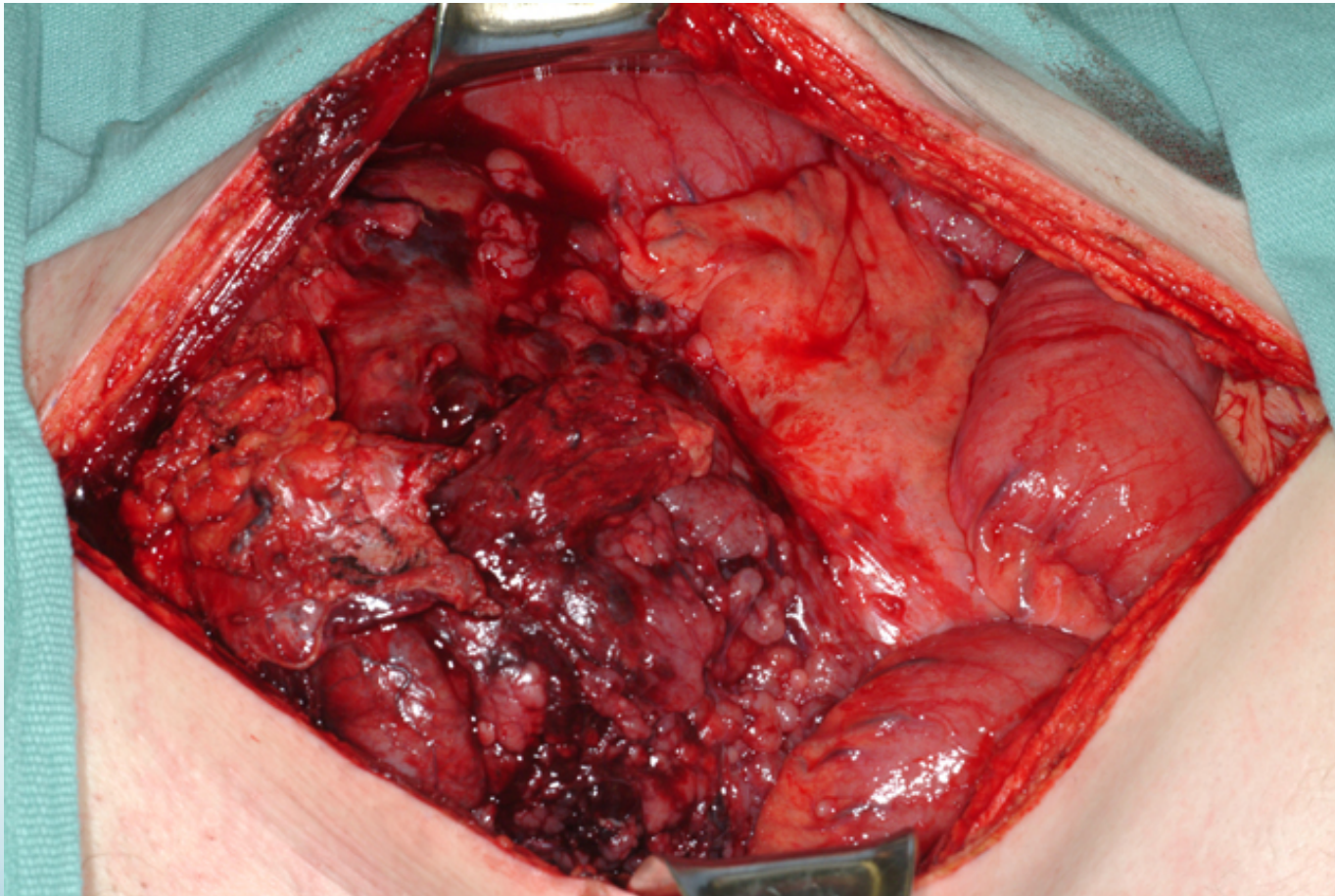
October 4



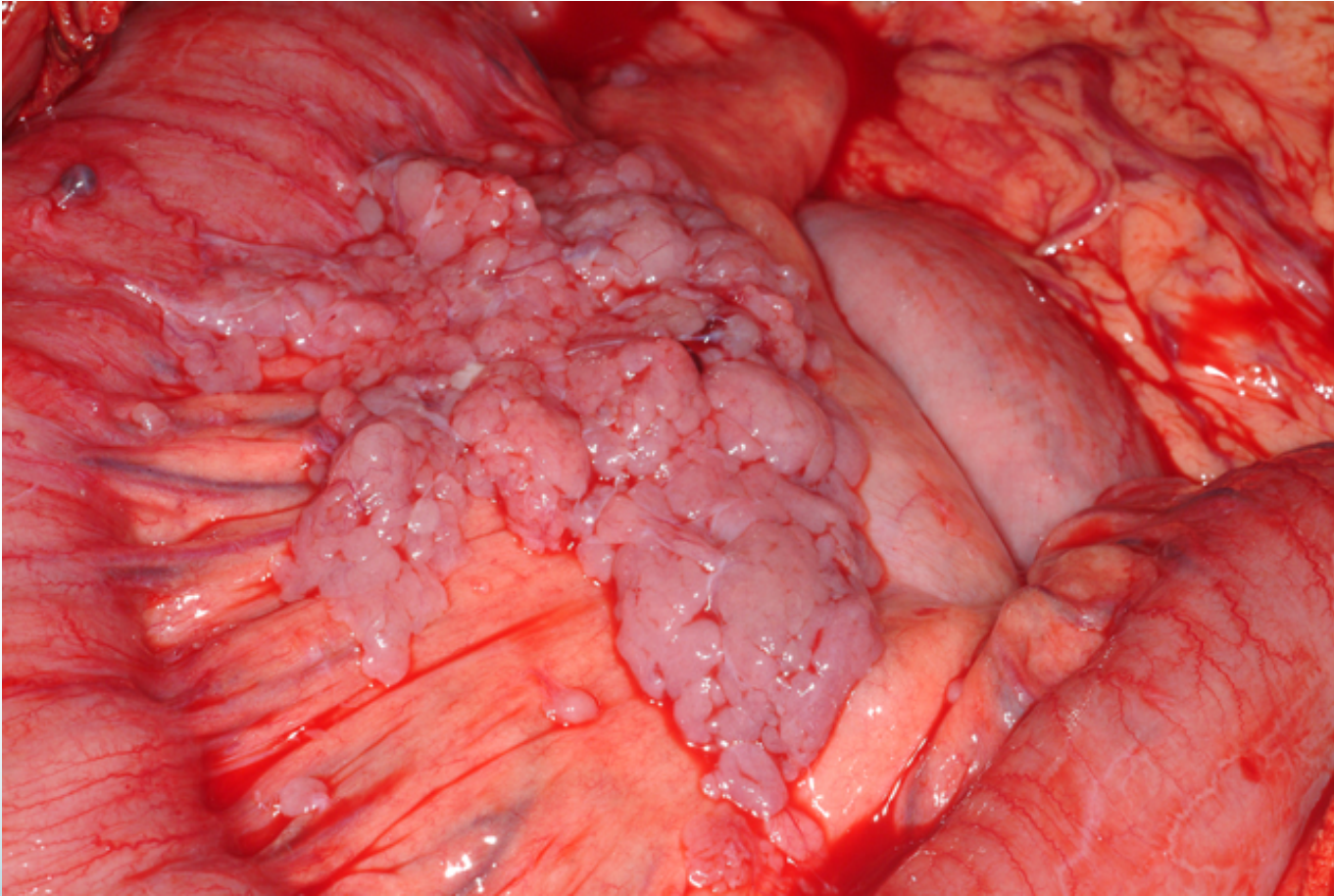
Before Therapy

After Therapy

GIST Prior to Therapy



GIST After Therapy



Treatment of GISTs

- Localized Resectable Disease

 - Surgical Resection**

- Locally Advanced Unresectable Disease

 - Gleevec (Imatinib mesylate)

 - Surgical resection of residual disease (if downstaged)

 - (little prospective data to support survival benefit)

- Metastatic Disease

 - Gleevec - FDA approved 2002

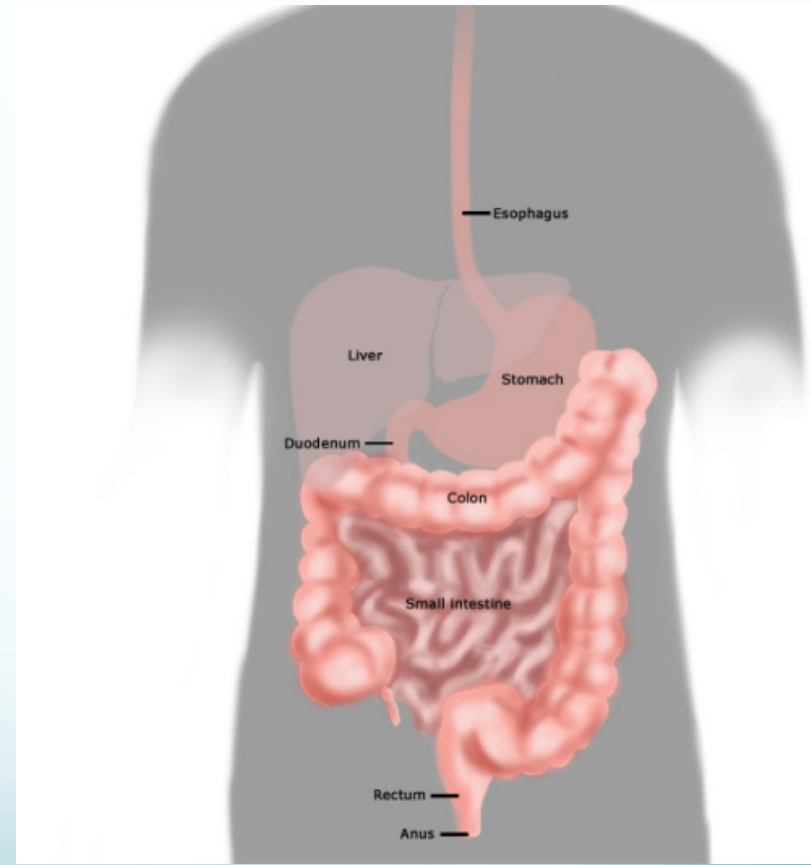
 - Possible surgical resection of residual disease
(if response)

 - Secondary resistance (median 24 months)

 - dose escalation, sunitinib or other trials

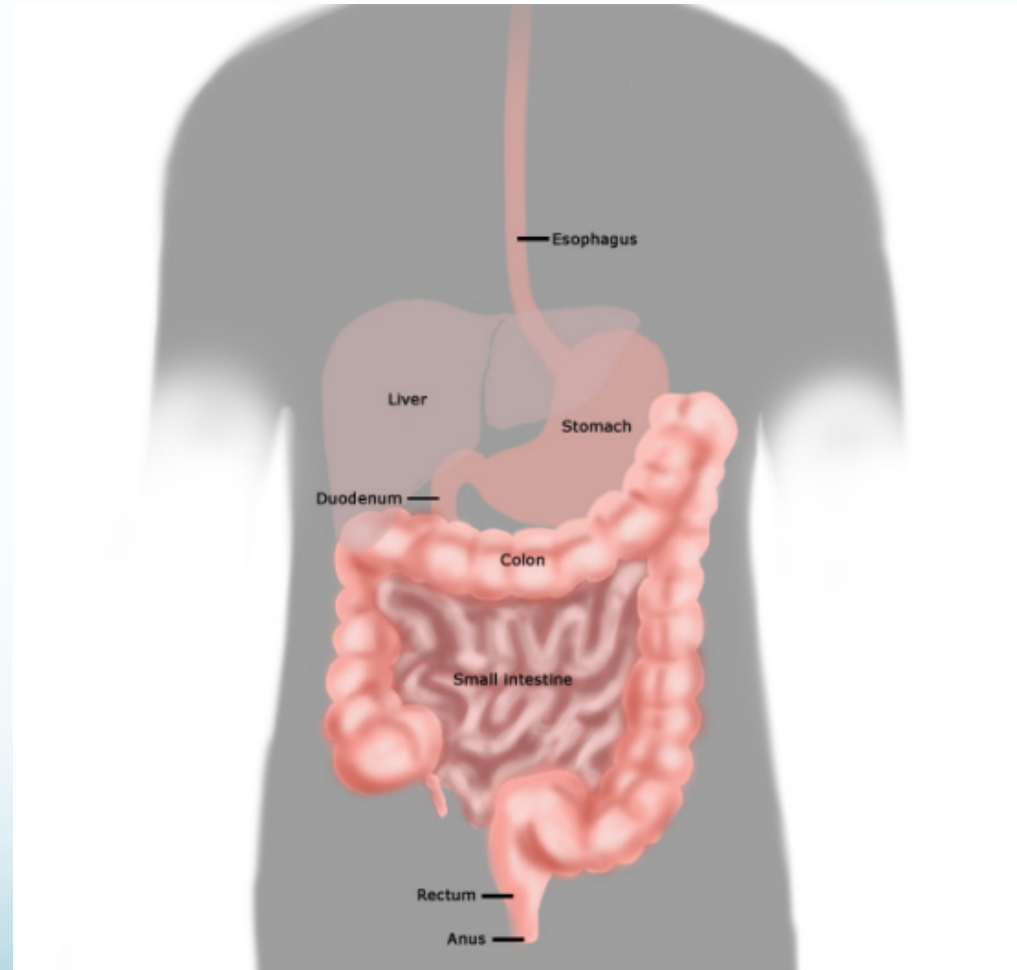
Esophageal GIST

- Tumors < 2cm that don't involve adjacent structures can be resected
- Tumors > 2cm and those close to juncture of stomach may require esophagectomy (through left abdominothoracic incision)
- Large tumors that involve other structures (such as diaphragm) may require imatinib treatment before surgery (neoadjuvant) to reduce the size of the tumor first.

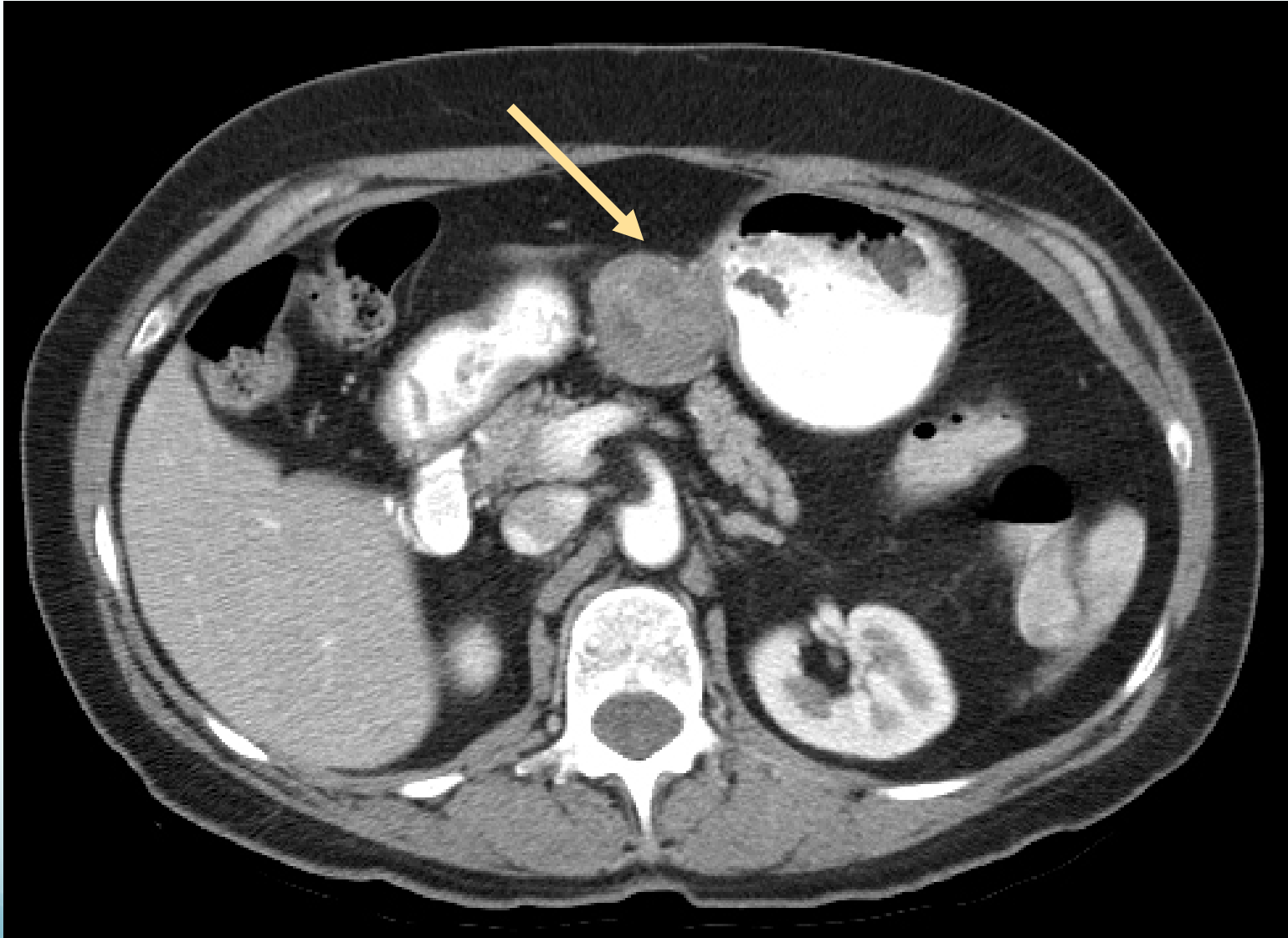


Gastric GIST

- < 2cm tumors may be managed nonoperatively
 - Endoscopic surveillance to monitor growth
- Tumors near esophagus may be surgically removed to avoid more extensive resection
- Tumors > 3cm or with chance of invading other organs such as liver or diaphragm should be considered for neoadjuvant imatinib
- Tumors in mid-body of stomach could be resected laproscopically

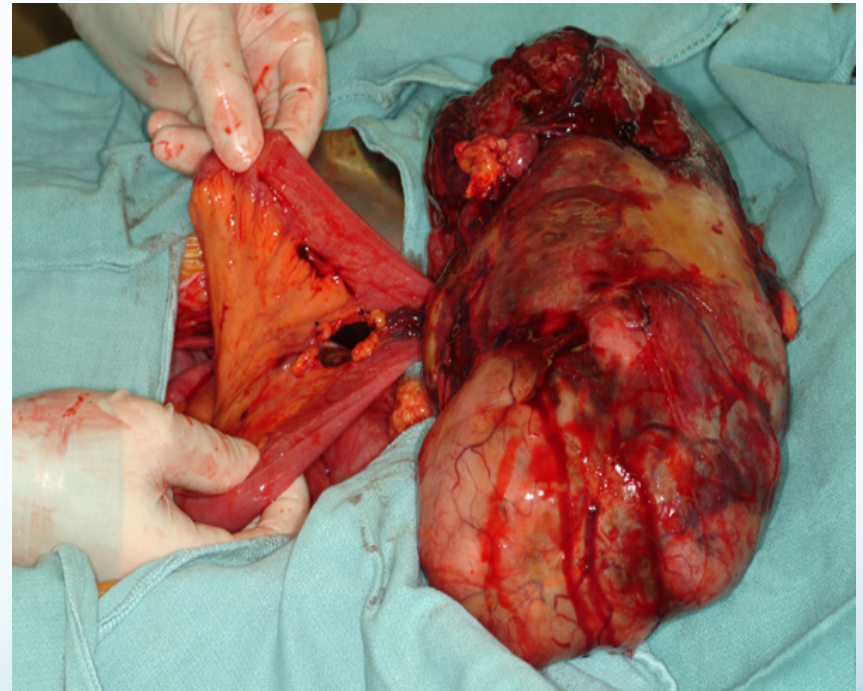


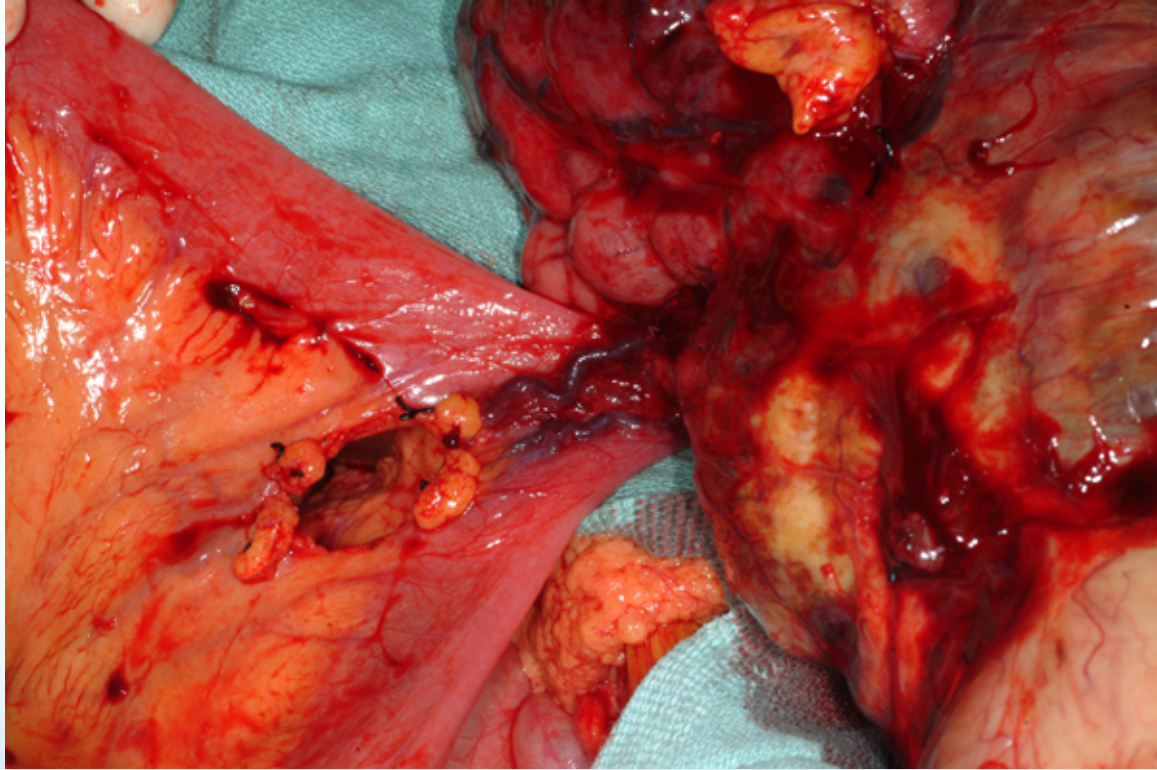
Gastric GIST



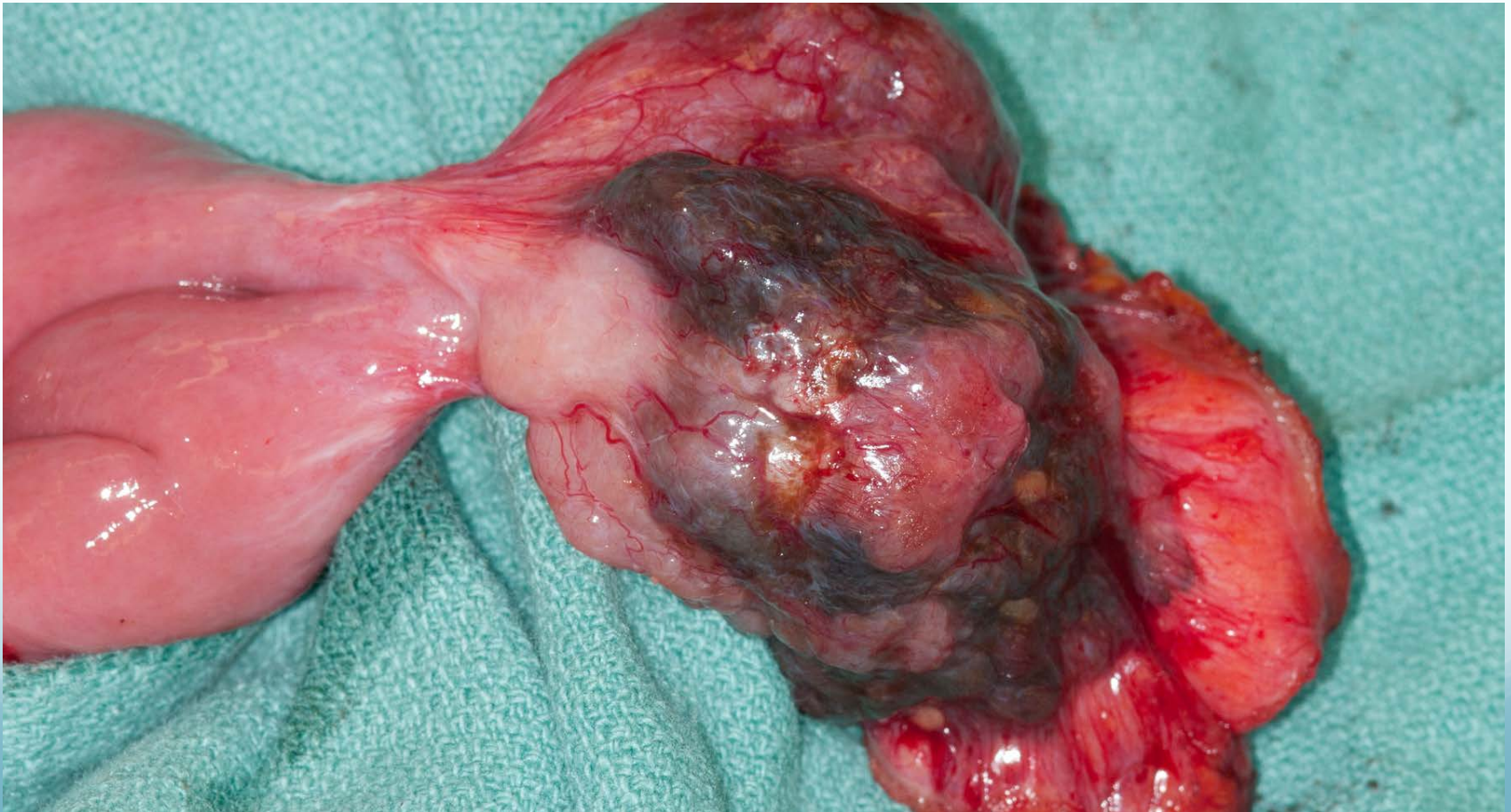
GIST of small intestine

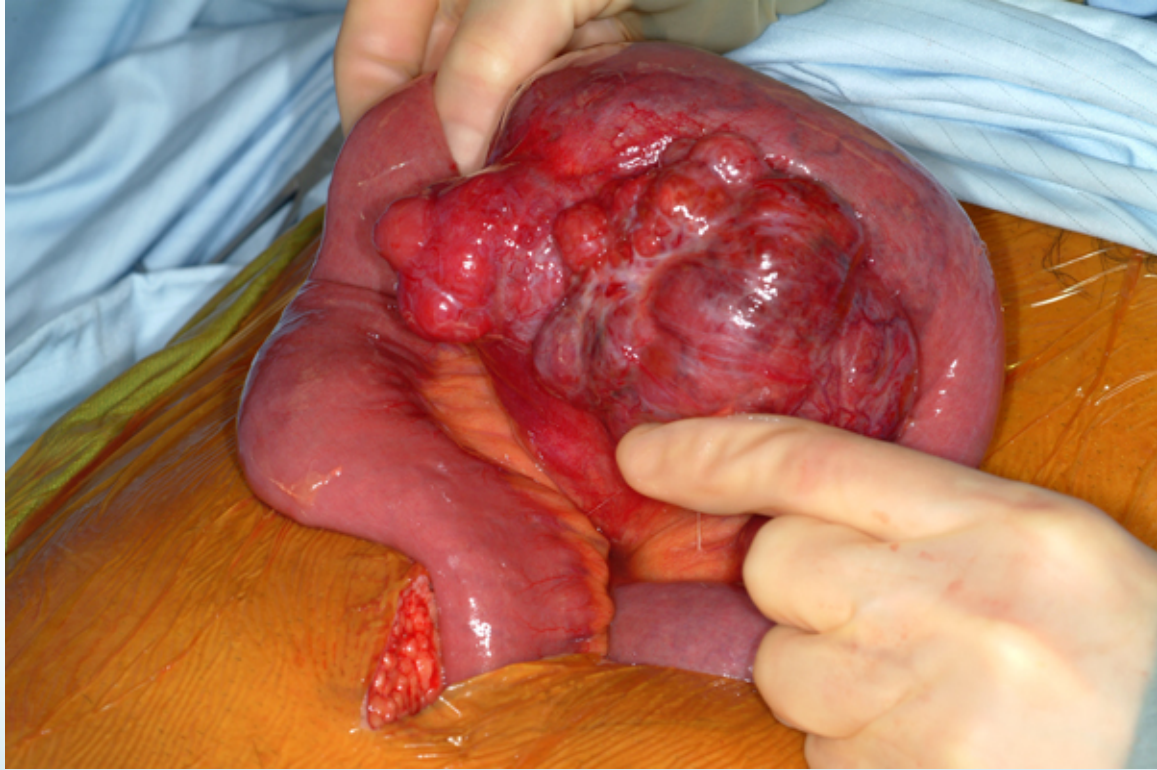
- Neoadjuvant imatinib may be considered for Duodenal GIST because of proximity to pancreas
- Tumors in jejunum and ileum are often relatively large because of later diagnosis
 - <5 cm possible laproscopic resection
 - Other organs may be involved and could benefit from neoadjuvant imatinib



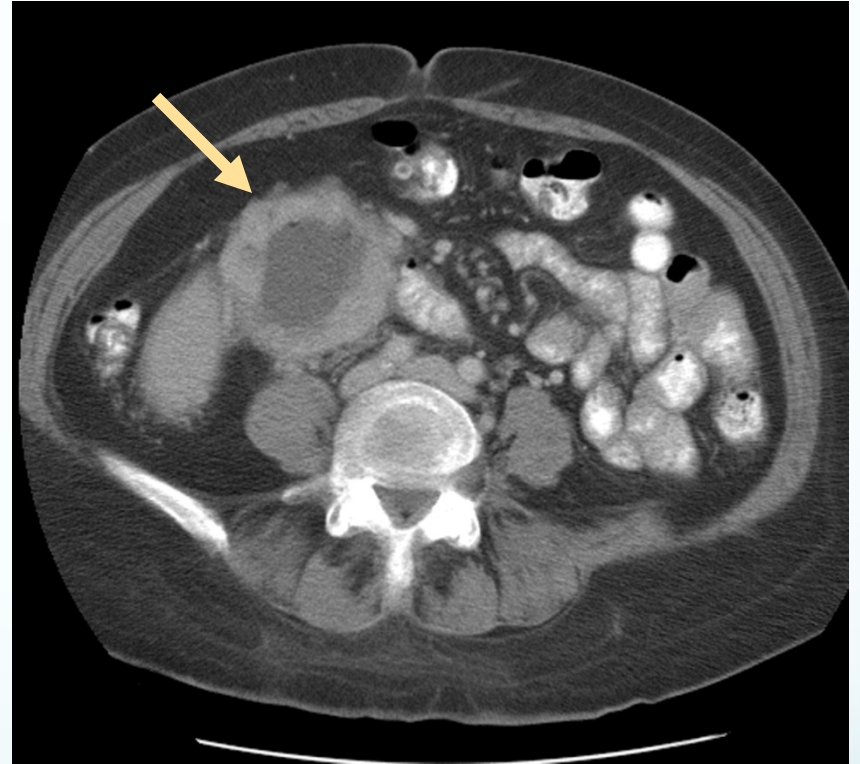
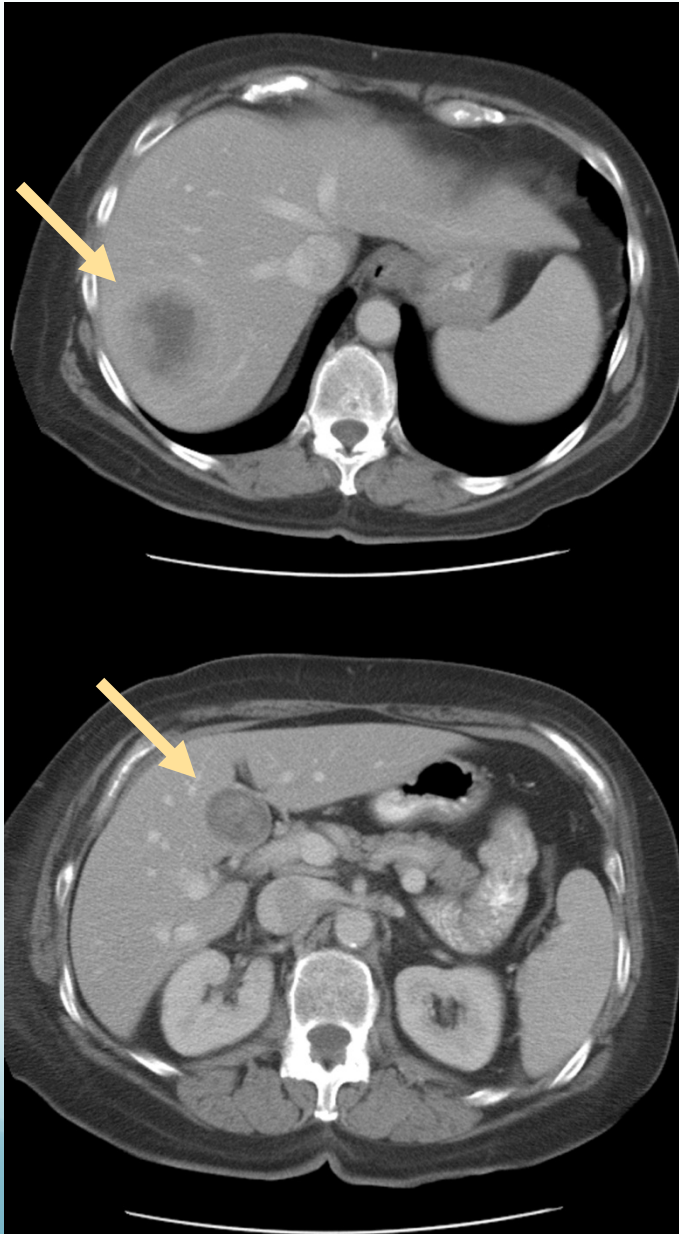


Small bowel GIST after therapy



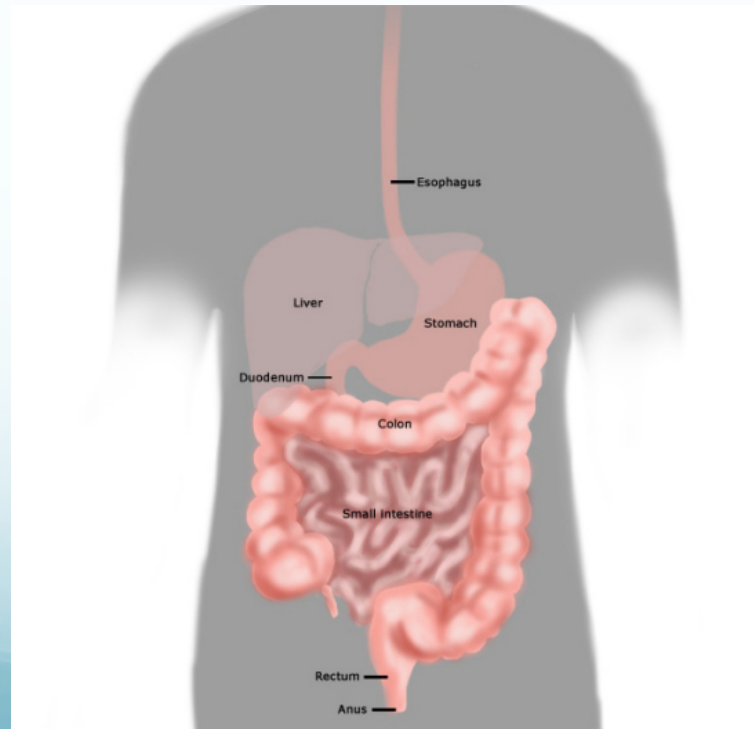


Duodenal Mass with Liver Metastases: GIST

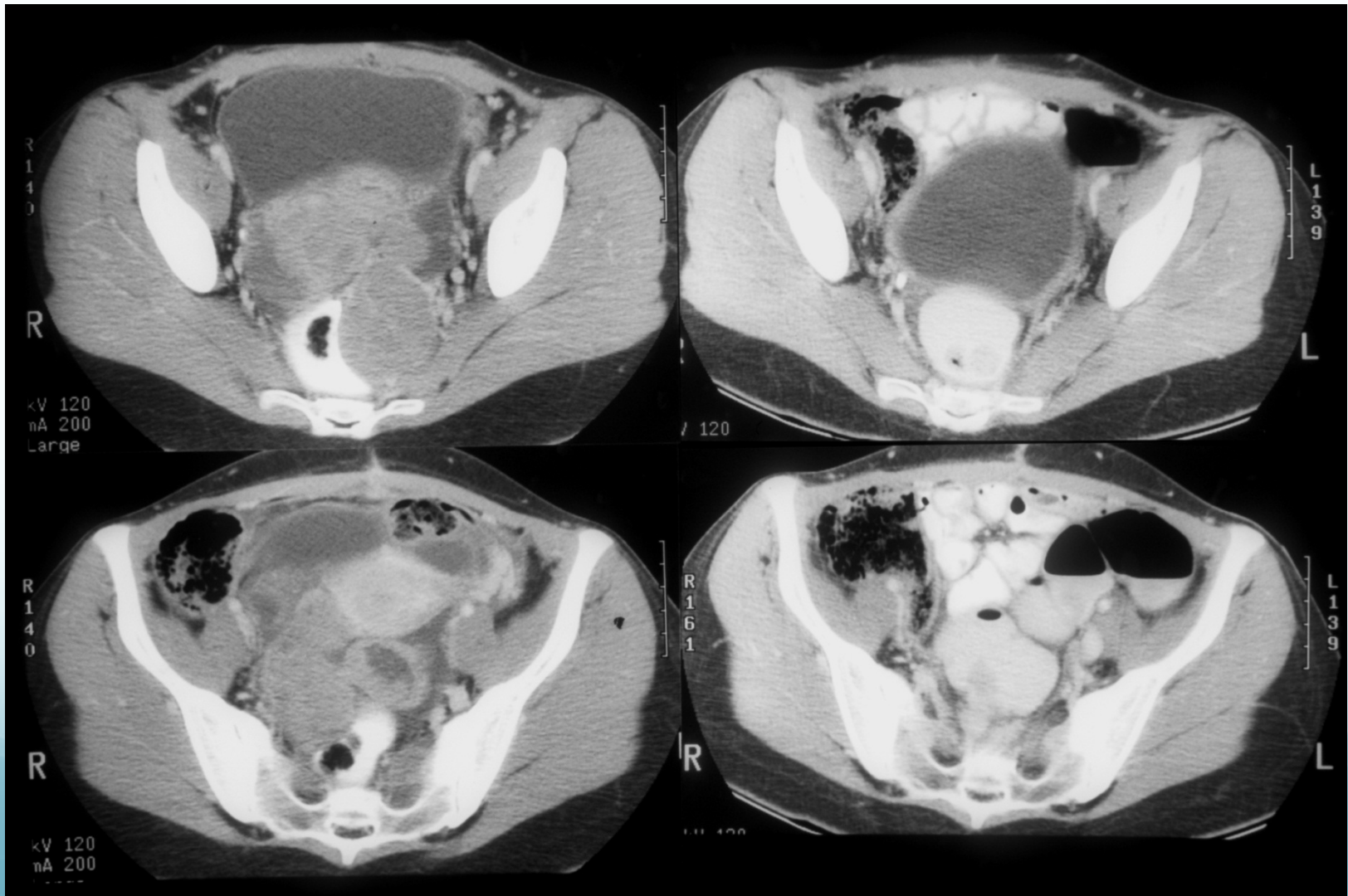


GIST of colon or rectum

- Tumors < 3cm can be considered for resection
- Tumors that may involve sphincters or other organs could be considered for neoadjuvant imatinib to reduce need for radical resection or colostomy.

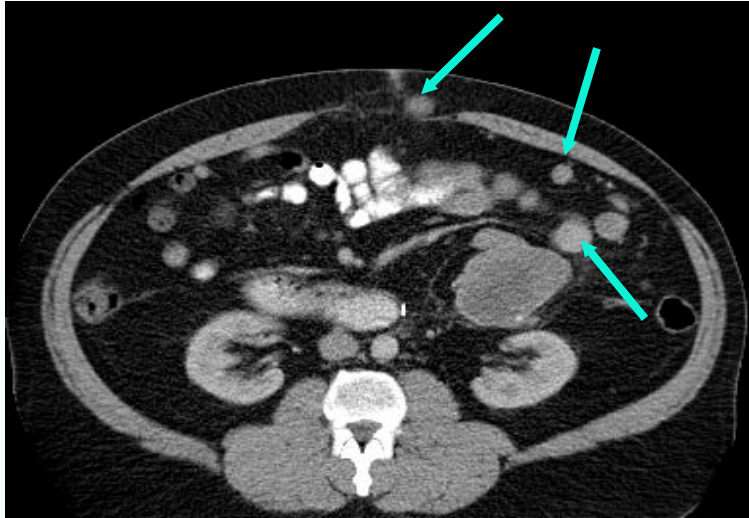


Rectal GIST before and after treatment

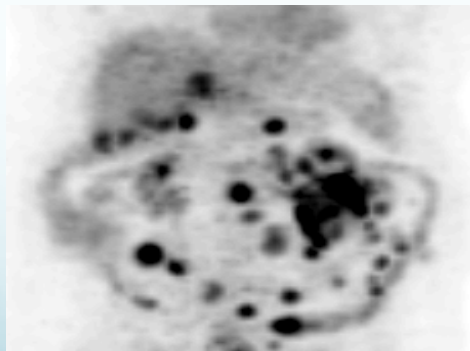
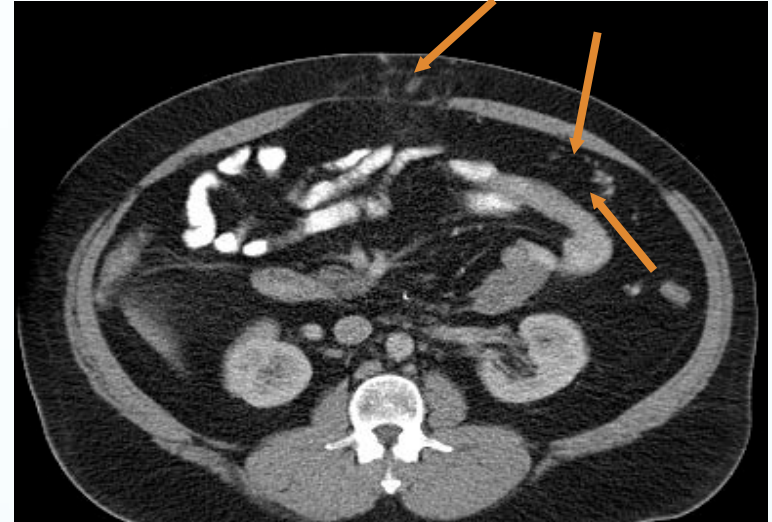


Utility of CT and PET Scan Follow-up in GIST

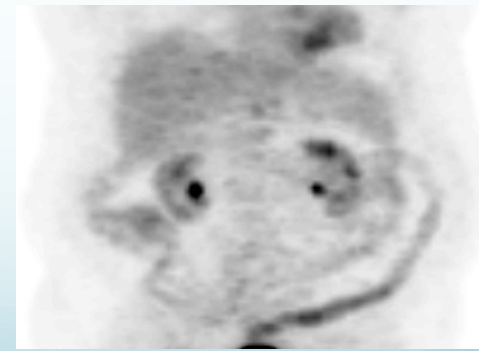
Initial



3 months



Before Gleevec



After Gleevec

Favorable Prognostic Factors following GIST Recurrence

- Disease-free interval >20 months from primary tumor resection to recurrence
- Recurrence limited to *either* peritoneal cavity or liver
- Complete resection of metastatic disease

Future of GIST Therapies

- Recent scientific advances have had a profound impact in patient care
- Molecular mechanisms of drug resistance
- Identification of new targets for therapy
- Development of novel agents
- Addressing subpopulations of GIST progenitor cells and stem cells

Future directions


- What is optimal duration of neoadjuvant imatinib treatment?
- Need to be able to measure response
 - PET-CT
- New prognostic systems needed for risk stratification
 - implementation of adjuvant therapy
- What is the optimal duration of adjuvant treatment?

Conclusions

- Complete surgical resection alone is the treatment of choice for localized GISTs
- Wide clinical spectrum of GISTs from benign to more malignant tumor behavior which can be predicted based on:
 - tumor size
 - mitotic activity
 - anatomic site
- High risk GISTs have high rate of recurrence requiring a combination of clinical and imaging directed to early identification of recurrences

Conclusions

- No standard management of recurrent GIST
- Important prognostic factors to consider when considering surgical resection of recurrent GIST
 - prior response to Gleevec
 - disease-free interval
 - location and number of tumor(s)
 - symptomatic tumors
 - availability other targeted agents or clinical trials



Thank you!

